



GLOBAL JOURNAL OF MEDICAL RESEARCH: F
DISEASES

Volume 23 Issue 9 Version 1.0 Year 2023

Type: Double Blind Peer Reviewed International Research Journal

Publisher: Global Journals

Online ISSN: 2249-4618 & Print ISSN: 0975-5888

Goldincision- A Multifactor Approach to Cellulite Treatment

By Roberto Chacur, Honório Sampaio Menezes, Danuza Dias Alves,
Manoela Fassina Barros, Gina Matzembacher, Nívea Maria Bordin da Silva Chacur,
Rodrigo Cadore Mafaldo, Leandro Dias Gomes, Vincenzo Stein de Vargas
& Gabriella Andressa Marchesin de Castro

Abstract- Background: Gynoid lipodystrophy (GLD), popularly known as cellulite, is the result of fat deposits under the skin. It is characterized by structural, inflammatory, and biochemical disorders of the subcutaneous tissue that cause irregular dimpling of the epidermis. Among many treatments used for GLD, Goldincision® has proved to be effective, showing more significant and satisfactory results. Therefore, this work aimed to describe this technique.

Methodology: This is a multicenter observational study which analyzed the cases of 47 patients who were submitted to the Goldincision® technique in 2021, using the team's protocol for assessment, treatment, and follow-up.

Keywords: cellulite, gynoid lipodystrophy, treatment, aesthetics, goldincision.

GJMR-F Classification: NLM: WR650



Strictly as per the compliance and regulations of:



© 2023. Roberto Chacur, Honório Sampaio Menezes, Danuza Dias Alves, Manoela Fassina Barros, Gina Matzembacher, Nívea Maria Bordin da Silva Chacur, Rodrigo Cadore Mafaldo, Leandro Dias Gomes, Vincenzo Stein de Vargas & Gabriella Andressa Marchesin de Castro. This research/review article is distributed under the terms of the Attribution-NonCommercial-NoDerivatives 4.0 International (CC BY-NC-ND 4.0). You must give appropriate credit to authors and reference this article if parts of the article are reproduced in any manner. Applicable licensing terms are at <https://creativecommons.org/licenses/by-nc-nd/4.0/>.

Goldincision— A Multifactor Approach to Cellulite Treatment

Roberto Chacur ^α, Honório Sampaio Menezes ^ο, Danuza Dias Alves ^ρ, Manoela Fassina Barros ^ω, Gina Matzembacher [¥], Nívea Maria Bordin da Silva Chacur [§], Rodrigo Cadore Mafaldo ^χ, Leandro Dias Gomes ^ν, Vincenzo Stein de Vargas ^ο & Gabriella Andressa Marchesin de Castro ^ζ

Abstract- Background: Gynoid lipodystrophy (GLD), popularly known as cellulite, is the result of fat deposits under the skin. It is characterized by structural, inflammatory, and biochemical disorders of the subcutaneous tissue that cause irregular dimpling of the epidermis. Among many treatments used for GLD, Goldincision® has proved to be effective, showing more significant and satisfactory results. Therefore, this work aimed to describe this technique.

Methodology: This is a multicenter observational study which analyzed the cases of 47 patients who were submitted to the Goldincision® technique in 2021, using the team's protocol for assessment, treatment, and follow-up.

Results: The cases of 47 female patients who underwent the Goldincision® technique were analyzed retrospectively. The average age of the participants was 39.48 years old. The regions where the technique was applied were the buttocks, thighs, posterior thighs, lateral thighs, and anterior thighs. Application area sizes ranged from small to medium, large, and extra-large. There was no significant association between the size of the application area and the number of sessions needed, with 2.23 being the average number of sessions required. Bleeding, hemosiderin staining, seroma formation, hematoma formation, nodule formation, and occasional pain were the complications associated with the technique.

Conclusion: This study described the Goldincision® technique as a treatment for gynoid lipodystrophy. The technique proved to be effective in the treatment of advanced gynoid lipodystrophy.

Keywords: cellulite, gynoid lipodystrophy, treatment, aesthetics, goldincision.

I. INTRODUCTION

Gynoid lipodystrophy (GLD), also known as adiposis edematosa and popularly called cellulite, is the result of fat deposits under the skin. It is characterized by structural, inflammatory, and biochemical disorders of the subcutaneous tissue that cause irregular dimpling of the epidermis. The noticeable changes consist of protrusions, caused by fat and subcutaneous structures protruding into the dermis, and depressions, caused by skin retraction due to subcutaneous fibrous septa.^{1,2,3,4}

Author α: MD, PhD, DSc, Clínica Leger, Rio Grande do Sul, Brazil.

e-mail: nucleodepesquisa@clinicaleger.com.br

Author ρ θ: MD, Clínica Leger, Rio Grande do Sul, Brazil.

Author χ ν: MD, PhD, Clínica Leger, Rio Grande do Sul, Brazil.

Author ζ: Biomedical, PhD, DSc, Clínica Leger, Rio Grande do Sul, Brazil.

Author α ω ¥ §: MD, Clínica Leger, Rio de Janeiro, Brazil.

The primary factor for the development of gynoid lipodystrophy is the presence of estrogen; therefore, it occurs almost exclusively in women. Its onset is common after puberty and can be exacerbated in periods of increased hormone levels such as during pregnancy, breastfeeding, menstruation, and the use of oral hormonal contraceptives. GLD affects mostly the subcutaneous tissues around the thighs, buttocks, and hips, where there is greater adipose tissue deposition in female patients due to the presence of estrogen.^{1,2,3}

One of the theories that may explain the appearance of cellulite is related to the occurrence of edema in the connective tissue, which causes a large water accumulation. Another hypothesis is the compression of the venous and lymphatic systems, mainly due to obesity, which alters the microcirculation.^{2,5} A third possibility is that it may be associated with the different arrangement of the connective tissue fibers – perpendicular in women and oblique in men^{6,7} – which could explain the higher incidence of GLD in female patients. The appearance of this condition can also be influenced by reduced collagen, stress, sedentary lifestyle, obesity, heredity, use of hormonal contraceptives, age, pregnancy, and nutrition, among other factors.⁸

Gynoid lipodystrophy is a complex and multifactorial condition, and its real causes and/or predispositions are yet to be determined. Therefore, it is still difficult to achieve significant efficacy in the treatments used.^{1,2}

There are non-invasive treatments, such as topical therapies, oral therapies, endermology, cryolipolysis, ultrasound, infrared light, intense pulsed light, extracorporeal pulse activation therapy, and radiofrequency, used to combat cellulite. Moreover, minimally invasive treatments such as carboxytherapy, mesotherapy, subcision, and Goldincision®^{2,3,9,10} can also be used to this end.

a) Goldincision®

Goldincision® is a technique developed for the treatment of more advanced grades of cellulite, according to the classification of Nürenberger and Müller.⁶ It combines subcision with biostimulation of neocollagenesis using particulate products: polylactic acid, calcium hydroxyapatite, polycaprolactone and,

mainly, polymethylmethacrylate to obtain a more satisfactory result^{11,12}.

Polymethylmethacrylate (PMMA) is a polymer used as a tissue filler in the form of synthetic microspheres with diameters between 40 and 60 μm . These microspheres may be suspended in a solution of collagen, be it protic or crystalloid, which is injected with microcannulas without cuts or surgeries. Currently, with the fourth generation of PMMA, a perfect granulometry can be observed. Due to its lack of impurities and regular surface, it provides a greater area of contact with the tissue and, consequently, faster tissue fixation¹³.

The commercial product may vary between 2%, 5%, 10%, 15%, and 30%, depending on the concentration of PMMA. It has a permanent effect, as only the vehicle is absorbed, and tissue biostimulation occurs around the particles. Considering its property of stimulating neocollagenesis through a controlled inflammatory response^{13,14}, PMMA can also be used as

a biostimulator when in small amounts and evenly distributed in the subdermal plane at a concentration of 10%.

Subcision is the undermining of fibrous septa in selected areas. This technique, despite apparent clinical improvement in some cases, leaves something to be desired. There may be cases of new adhesion of the same treated septum, ineffectiveness, and frequent complications such as seromas and hematomas, in addition to limited results in isolated areas without relevant neocollagenesis^{12,15}.

Goldincision® is used not only for sectioning fibrous septa (Figure 1) but also for general collagen biostimulation (Figure 2), improving sagging, circulation, local metabolism and lymphatic drainage (involved in cellulite genesis). Post-procedure care prevents adverse effects and scars, making Goldincision® a successful treatment which results in a high degree of satisfaction among patients and professionals¹².

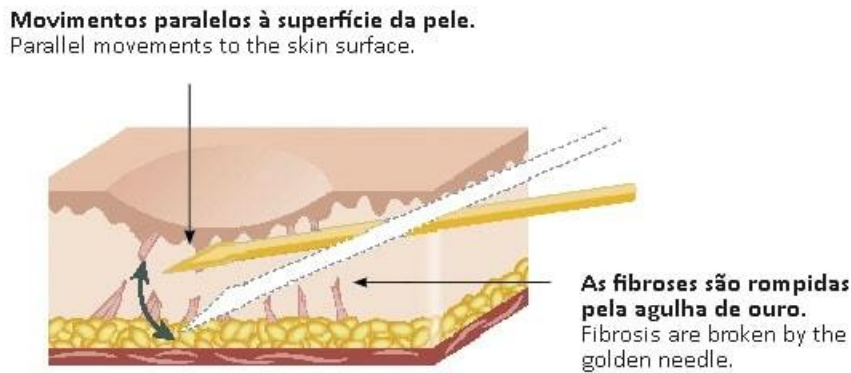


Figure 1: Sectioning of the septa with the Goldincision technique. Source: <https://goldincision.com.br/tratamento-celulite-subcisao-preenchimento/>

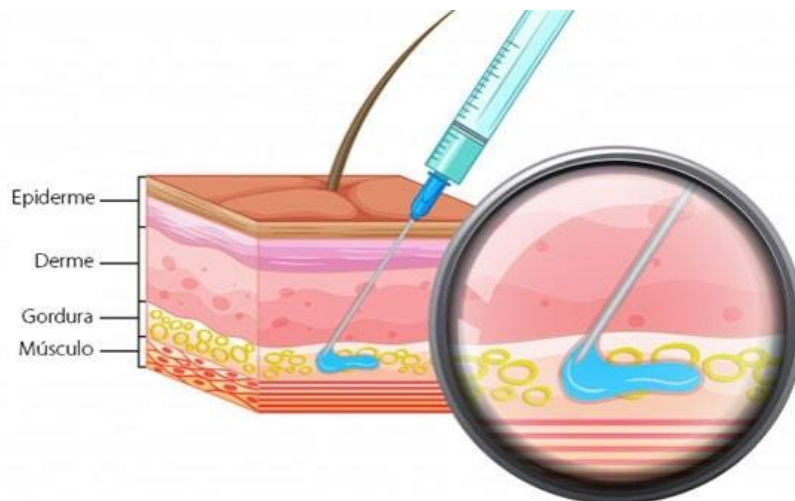


Figure 2: Application of collagen biostimulant with PMMA using the Goldincision technique. Source: <https://goldincision.com.br/tratamento-celulite-subcisao-preenchimento/>

II. METHODOLOGY

This is a multicenter observational study. The case records of 47 patients who were submitted to the Goldincision® technique in 2021, using the team's protocol for evaluation, treatment, and follow-up, were evaluated. This study was approved by the Research Ethics Committee under protocol number 30867114.3.0000.5333.

Inclusion criteria were female patients with advanced grades of gynoid lipodystrophy. Exclusion criteria were patients who had hyaluronic acid, hydrogels, and biopolymers in the treated region. Pregnant patients were also excluded, along with those who were breastfeeding or had a low degree of gynoid lipodystrophy.

The evaluation criteria were the age of the patients, recommended treatment area size, number of sessions performed, volume used in each session, and adverse effects.

a) Description of the technique

After the individual assessment of the patient by the professional, the former signed an informed consent form and had their photographic record taken. The Goldincision® procedure may be summarized as follows

- A – Preparation for the procedure;
- B – Marking of skin depressions;
- C – Asepsis;
- D – Local anesthesia;
- E – Biostimulation of neocollagenesis;
- F – Sectioning of the fibrous septa;
- G – Compressive dressings.

A. Preparation of the room and opening of sterile supplies for the procedure.

Sterile field, gloves, and gauze are used to prepare the materials. For the procedure, an 18G malleable cannula with a blunt, atraumatic tip, an 18G needle, 2% lidocaine, sterile saline for the dilution of the anesthetic, anesthesia syringe, and biostimulator are used.

B. Marking of the skin depressions.

The depressions are marked immediately before the procedure with the patient standing in a relaxed position.

With the patient in an upright position, the septa are marked for further sectioning.

C. Local disinfection.

With the patient in the prone position, skin disinfection of the site is performed before the procedure.

D. Local anesthesia is performed by cutaneous infiltration of lidocaine.

After disinfection of the area, local anesthesia is performed using 2% lidocaine with vasoconstrictor

diluted in sterile saline (1:1). An 18G needle is used to open the entry point for an 18G malleable cannula with a blunt, atraumatic tip. Local anesthesia infiltration is performed considering the maximum amount of anesthetic calculated by the patient's weight, generally 0.2 mL of lidocaine per kg or 0.4 mL of solution per kg.

E. Biostimulation of neocollagenesis.

After local anesthesia, the biostimulation of neocollagenesis with 15% PMMA is carried out, helping to stimulate the production of neocollagen and the improvement of local circulation. The objective of this step is to improve the overall quality of the skin, improve vascularization, collagen and metabolism in the entire region.

This step is performed with the patient in the prone position using an 18G malleable cannula with a blunt, atraumatic tip. The biostimulator is injected in a retrograde, fan-like fashion to homogeneously distribute the particulate product into the subcutaneous tissue throughout the region and not only in the depressions, and before fibrous septum detachment. Thus, it is possible to avoid the accumulation of product and the formation of nodules.

F. Sectioning of the fibrous septa using a needle.

After the biostimulation of the region, the sectioning of the subcutaneous septa is done using an 18G needle. For a clear view of the sectioning, it should be performed with the patient standing, so that skin undermining is kept to a minimum, just enough to even out apparent irregularities. During the procedure, some blood vessels close to the septa might be cut, resulting in the formation of transient ecchymoses with a risk of hematoma and seroma. These may be avoided with local compression during the first 24 hours. The presence of one or more surgical assistants throughout the procedure is important to maintain immediate compression of the septa after skin undermining.

G. Compression dressings on undermined areas.

A compression dressing is applied to the undermined area (figure 3). The patient is instructed to keep it for 24 hours before removal. A compression garment is also worn right after the procedure. The patient must continue wearing it for at least seven days.

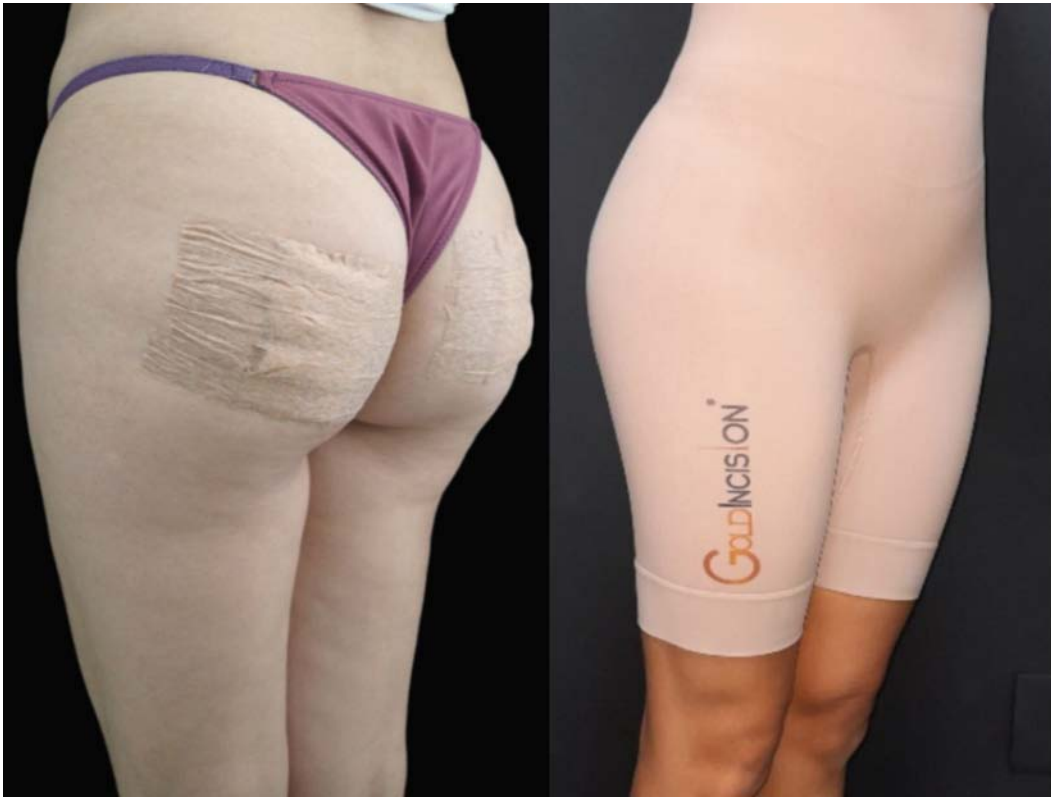

Figure 3: Compression dressing on the undermined areas and compression garment. Source: Own figure.

After the procedure, the patient is instructed to wear the compressive shorts for at least seven days and not to do any physical activity until the dressings are

removed (24 hours), as well as being encouraged to perform local lymphatic drainage.

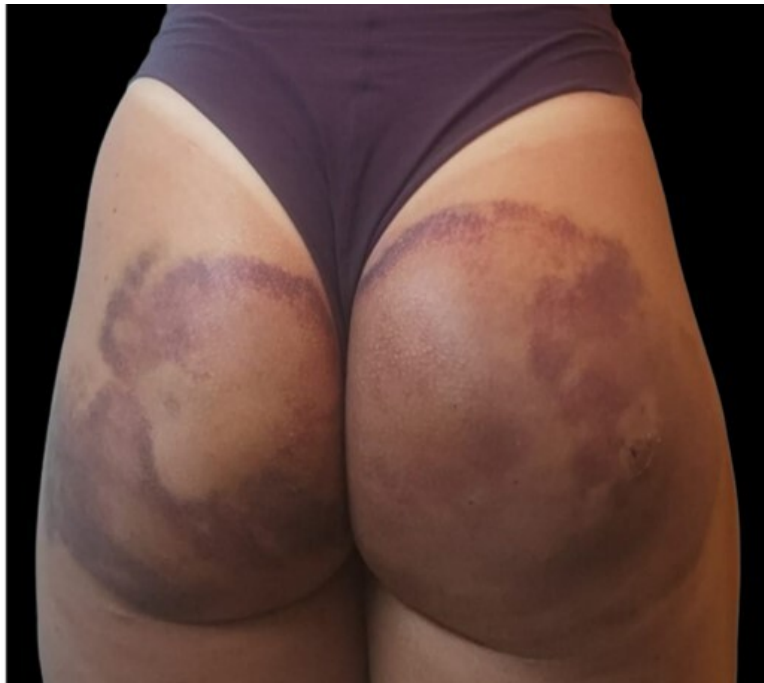

Figure 4: Ecchymosis after 7 days of Goldincision treatment. Source: Own figure.

b) *Goldincision kit*

The post-treatment guidelines were associated with the use of the post-Goldincision® kit (figure 5). It consists of the use of an antithrombotic ointment made with heparin, vitamin K1, and Methyl Nicotinate, the

ingestion of arnica pellets containing CH5, Echinacea D2, and Calendula D2, and subsequent use of a depigmenting cream with tranexamic acid, thioglycolic acid, and Haloxyl. This way, it is possible to minimize the main adverse effects of the procedure.



Figure 5: Post-Goldincision kit. Source: Own figure.

III. RESULTS

The cases of 47 female patients who underwent the Goldincision® technique were analyzed retrospectively. The average age of the participants was 39.48 years old. The regions where the technique was applied were the buttocks (n=32; 68.08%); the buttocks

and posterior thighs (n=6; 12.76%); the buttocks and posterior and lateral thighs (n=2; 4.25%); posterior thighs (n=2; 4.25%); buttocks and thighs (n=4; 8.51%); and buttocks, anterior and posterior thighs (n=1; 2.12%), as seen in Table 1.

Table 1: Region of application of the Goldincision® technique.

Region	N	%
Buttocks	32	68.08%
Buttocks and posterior thighs	6	12.76%
Buttocks and posterior and lateral thighs	2	4.25%
Posterior thighs	2	4.25%
Buttocks and thighs	4	8.51%
Buttocks and anterior and posterior thighs	1	2.12%

The application area sizes ranged from small (n=8; 17.02%) to medium (n=26; 55.31%), large (n=11; 23.40%), and extra-large (n=2; 4.25%), as shown in Table 2. There was no significant association between

the size of the application area and the number of sessions needed, with 2.23 being the average number of sessions.

Table 2: Size of the area of application of the Goldincision® technique.

Size	N	%
Small	8	17.02%
Medium	26	55.31%
Large	11	23.40%
Extra large	2	4.25%

The number of sessions is related to the body's response to the applied stimulus. All the patients (n=47) were submitted to the first session (Figure 6) of the technique (subcision=47, biostimulus=44); 80.85% (n=38) underwent a second session (Figure 7) (subcision=38, biostimulus=28); 38.29% (n=18)

underwent a third session (Figure 8) (subcision=18, biostimulation=7); and 4.2% (n=2) underwent a fourth session (Figure 9) which consisted only of the subcision of some remaining septa. A fifth session was not necessary for any of the patients in the analysis group.

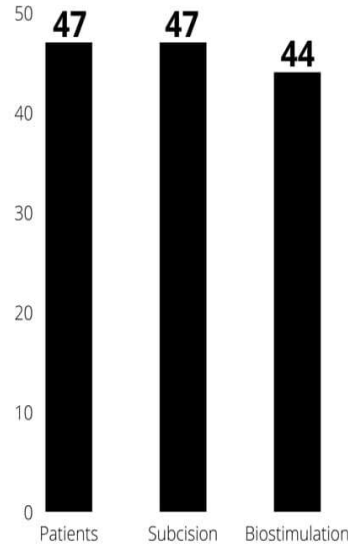


Figure 6: First session using the Goldincision® technique. Source: Own figure.

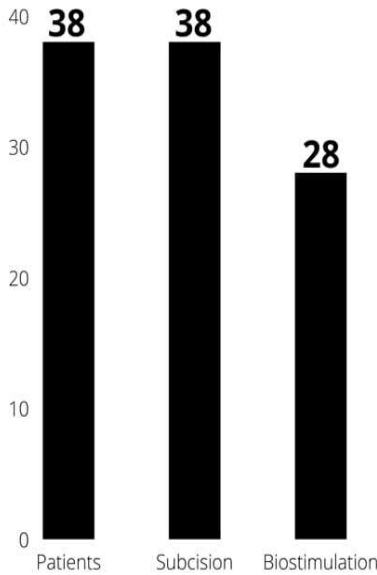


Figure 7: Second session using the Goldincision® technique. Source: Own figure.

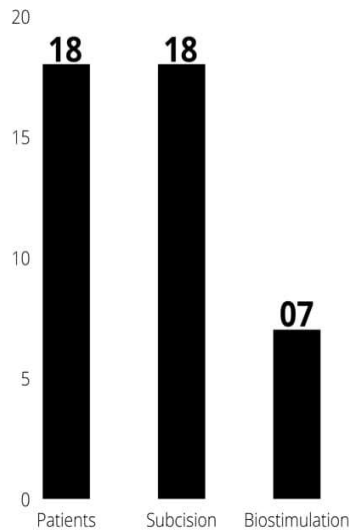


Figure 8: Third session using the Goldincision® technique. Source: Own figure.

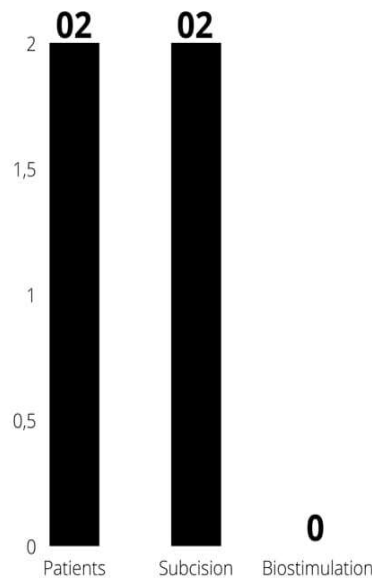


Figure 9: Fourth session using the Goldincision® technique. Source: Own figure.

The mean volume of 15% polymethylmethacrylate used per session was 39.48 mL in the first session, 21.82 mL in the second session, and 12.85 mL

in the third session. Biostimulation of neocollagenesis with the particulate product was not used in the fourth session, as shown in Table 3.

Table 3: Mean volume used per session of the Goldincision® technique.

Volume per session	N	Mean volume 10%
Session 1	44	39.48 mL 15%
Session 2	28	21.82 mL 15%
Session 3	7	12.85 mL 15%
Session 4	No biostimulation	-

As shown in Table 4, internal bleeding (n=47; 100%), hemosiderin staining (n=7; 14.89%), seroma formation (n=1; 2.12%), hematoma formation (n=1;

2.12%), nodule formation (n=1; 2.12%), and occasional pain (n=1; 2.12%) were the complications associated with the technique.

Table 4: Complications associated with the Goldincision® technique.

Complication	N	%
Bleeding	47	100%
Hemosiderin staining	7	14.89%
Seroma formation	1	2.12%
Hematoma formation	1	2.12%
Nodule formation	1	2.12%
Occasional pain	1	2.12%

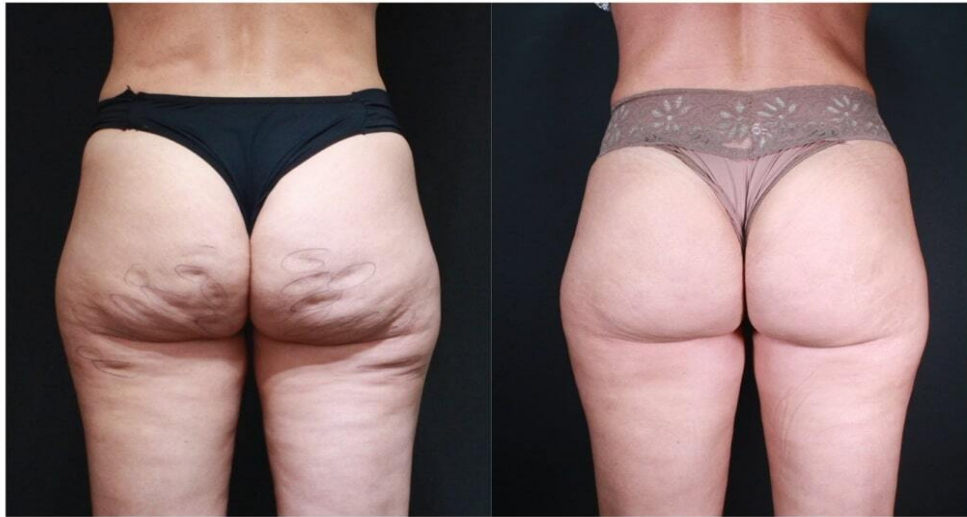

Figure 10: Patient, 42 years old, submitted to 2 sessions of Goldincision treatment. In the first session, 39ml of PMMA was used to biostimulate the region and the fibrous septa were sectioned. The second session was performed 42 days after the first, with only the section of the remaining septa, no product was used again. First photo taken before the procedure and the second photo taken 3 months after the second session. Source: Own figure.

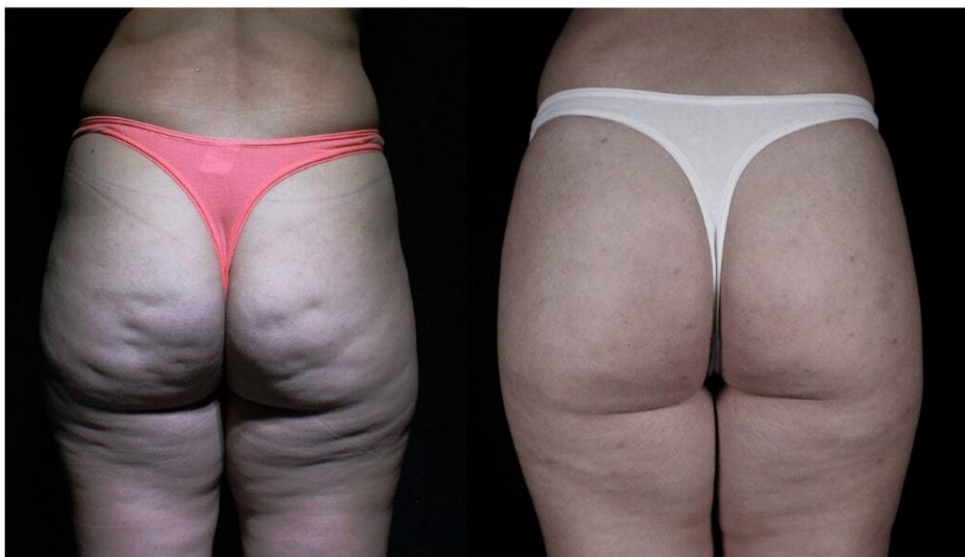

Figure 11: Patient, 43 years old, submitted to 1 session of Goldincision treatment. 45ml of PMMA was used to biostimulate the region and the fibrous septa were sectioned. First photo taken before the procedure and the second photo taken after 71 days. Source: Own figure.



IV. DISCUSSION

Gynoid lipodystrophy presents a clinical aspect of irregular appearance of the epidermis. A fibrotic band can be seen in 97.6% of the cases, especially when related to poor local circulation and metabolic insufficiency^{16,17}.

According to the Brazilian Society of Dermatology, gynoid lipodystrophy affects 95% of women after puberty, having a significant negative impact on personal, professional, and social levels¹⁸.

As it is a condition with a high level of complexity, studies on the creation and improvement of treatment techniques are regularly carried out. In 1997, the subcision technique was described for the treatment of gynoid lipodystrophy grades 3 and 4 (according to the Nürenberger and Müller classification). It consists of skin undermining for the sectioning of the fibrous septa in selected areas; however, this technique alone has limited results since the production of neocollagen is not significant¹⁹.

We do not use the term Subcision™ because this technique has the concept of not using a product and/or association of fillers and biostimulators¹⁴. The Goldincision® technique was developed to meet the needs of patients with advanced lipodystrophy. The noteworthy effects of the technique are related to its methodology, which associates stimulation of neocollagenesis with subcision, providing the undermining of fibrotic retraction but also improving the quality of the skin as a whole, improving not only the point-to-point treatment in a more effective way with the patient standing and a whole evaluation and follow-up protocol, but acting on the genesis of cellulite, resulting in an improvement of cellulite in all degrees with restructuring of collagen, a component of local metabolism, and neovascularization¹².

V. CONCLUSION

This study described the Goldincision® technique for the treatment of gynoid lipodystrophy. It proved to be effective and safe in improving the quality of the skin and sectioning the fibrous septa; thus, providing a homogeneous skin appearance. The treatment must be prescribed and performed by a professional who is trained to perform the technique, understands the associated adverse effects, and has the resources and scientific knowledge to deal with them, ensuring patient safety.

The positive clinical effects of Goldincision® on the treatment of gynoid lipodystrophy were evident, and its use is very promising as the main minimally invasive treatment for this condition.

Financial Disclosure and Products Page

All authors have no commercial interests or financial relationships with any of the products, devices

or drugs mentioned in this manuscript. Therefore, there is no conflict of interest with the information presented in the submitted manuscript. Own financing.

REFERENCES RÉFÉRENCES REFERENCIAS

- Mendonça Ana Maria da Silva, Pádua Michelle de, Ribeiro Ana Paula, Milani Giovana Barbosa, João Sílvia Maria Amado. Confiabilidade intra e interexaminadores da fotogrametria na classificação do grau de lipodistrofiaginóide em mulheres assintomáticas. *Fisioter. Pesqui.* 2009 June; 16(2): 102-106. Doi: 10.1590/S1809-29502009000200002.
- Pérez Atamoros FM, Alcalá Pérez D, AszSigall D, Ávila Romay AA, Barba Gastelum JA, de laPeña Salcedo JA, Escalante Salgado PE, Gallardo Palacios GJ, Guerrero-Gonzalez GA, Morales De la Cerda R, Ponce Olivera RM, Rossano Soriano F, Solís Tinoco E, Welsh Hernández EC. Evidence-based treatment for gynoid lipodystrophy: A review of the recent literature. *J Cosmet Dermatol.* 2018 Dec; 17(6): 977-983. Doi: 10.1111/jocd.12555.
- João Paulo Junqueira M Afonso, Thaís Cardoso de Mello Tucunduva, Maria Valéria Bussamara Pinheiro, Ediléia Bagatin. Cellulite: a review. *Surg Cosmet Dermatol.* 2010; 2(3)214-19
- Hexsel DM, Dal'forno T, Hexsel CL. A validated photonumeric cellulite severity scale. *J Eur Acad Dermatol Venereol.* 2009 May; 23(5): 523-8. Doi: 10.1111/j.1468-3083.2009.03101.x.
- Tokarska K, Tokarski S, Woźniacka A, Sysa-Jędrzejowska A, Bogaczewicz J. Cellulite: a cosmetic or systemic issue? Contemporary views on the etiopathogenesis of cellulite. *Postepy Dermatol Alergol.* 2018 Oct; 35(5):4 42-446. Doi: 10.5114/ada.2018.77235.
- Nürnberg F, Müller G. So-called cellulite: an invented disease. *J Dermatol Surg Oncol.* 1978; 4: 221-229.
- Nürnberg F. Practically important diseases of the subcutaneous fatty tissue (including so-called cellulite). *Med. Welt.* 1981, 32, 682-688.
- De la Casa Almeida, M.; Suarez Serrano, C.; Rebollo Roldán, J.; Jiménez Rejano, J.J.; Cellulite's aetiology: a review. *J. Eur. Acad. Dermatol. Venereol.* 2013, 27, 273-278.
- Schonvetter Bianca, Soares Juliana Laudicéia Marques, Bagatin Ediléia. Longitudinal evaluation of manual lymphatic drainage for the treatment of gynoid lipodystrophy. *An. Bras. Dermatol.* 2014 Oct; 89(5): 712-718. Doi: 10.1590/abd1806-4841.2014 3130.
- Friedmann DP, Vick GL, Mishra V. Cellulite: a review with a focus on subcision. *Clin Cosmet Invest Dermatol.* 2017; Jan; 7 (10): 17-23. Doi: 10.2147/CCID.S95830.

11. Orentreich DS, Orentreich N. Subcutaneous incisionless (subcision) surgery for the correction of depressed scars and wrinkles. *Dermatol Surg.* 1995 Jun; 21(6): 543-9. doi: 10.1111/j.1524-4725.1995.tb00259.x. PMID: 7773602.
12. Roberto Chacur, Honorio Sampaio Menezes, Danuza Dias Alves, Nivea Maria Bordin da Silva Chacur, Renata D'Oliveira Bataioli, Raissa Nardi. Cellulite treatment using subcision and polymethyl methacrylate filling (goldincision®): case report. *Indian Journal of Applied Research: Volume-9 | Issue-9 | September - 2019.* Doi: 10.36106/ijar/6405958
13. Lemperle G, Morhenn V, Charrier U. Human histology and persistence of various injectable filler substances for soft tissue augmentation. *Aesthetic Plast Surg.* 2003; 27: 354–366; discussion 367.
14. Chacur, Roberto. *Ciência e Arte do Preenchimento.* 1ª edição. AGE EDITORA, 19 de abril, 2018.
15. Hexsel DM, Mazzuco R. Subcision: a treatment for cellulite. *Int J Dermatol.* 2000 Jul; 39(7): 539-44. doi: 10.1046/j.1365-4362.2000.00020.x.PMID: 10940122.
16. Lauren A. Whipple, Craig T. Fournier, Adee J. Heiman, Amanda A. Awad, Malcolm Z. Roth, Sebastian Cotofana, Joseph A. Ricci. the Anatomical Basis of Cellulite Dimple Formation: An Ultrasound-Based Examination. *Plastic and Reconstructive Surgery: September 2021 - Volume 148 - Issue 3 - p 375e-381e* Doi: 10.1097/PRS.00000000000008218.
17. Emanuele E, Minoretti P, Altabas K, Gaeta E, Altabas V. Adiponectin expression in subcutaneous adipose tissue is reduced in women with cellulite. *Int J Dermatol.* 2011; 50:412–416.
18. Sociedade Brasileira de Dermatologia, 2021. Página inicial/doenças/celulite. Disponível em: <https://www.sbd.org.br/doencas/celulite/>. Acesso em: 03 de fev. de 2022
19. Emanuele E. Cellulite: Advances in treatment. Facts and controversies. *Clin Dermatol.* 2013; 31: 725–730.